

A systematic study of topographical memory and posterior cerebral artery infarctions

Thomas Busigny, PhD
Bérengère Pagès
Emmanuel J. Barbeau,
PhD
Clara Bled
Emilie Montaut
Nicolas Raposo, MD
Jean-François Albucher,
MD
François Chollet, MD,
PhD
Jérémy Pariente, MD,
PhD

Correspondence to
Dr. Busigny:
busigny@cerco.ups-tlse.fr

ABSTRACT

Objective: To estimate the prevalence of topographical memory impairment following posterior cerebral artery infarctions (PCAI) and define its anatomical correlations.

Methods: We recruited 15 patients (mean duration of 4 months postinfarct). We administered 2 sets of experimental tests to assess topographical memory: one set included 5 computerized tasks (CompT) and the other set consisted of one ecological topographical orientation test (EcolT) that included 4 tasks (i.e., map drawing, picture recognition and ordering, backward path). Fifteen healthy participants served as controls. Patients and controls underwent a volumetric T1 MRI brain scan. Brain lesions in patients were segmented, normalized, and correlated with performance.

Results: Topographical memory impairments were evidenced in patients with PCAI using both group and individual analyses (50%), with more severe outcomes in patients with PCAI in the right hemisphere. CompT and EcolT were highly correlated, but the ecological test was more sensitive in revealing topographical memory impairments. Voxel-based lesion-symptom mapping demonstrated that 2 regions located in the cuneus and the calcarine sulcus correlated significantly with behavioral performance.

Conclusions: Topographical memory disorders following PCAI are reported in 50% of the patient population. Our results demonstrate the importance of developing and using dedicated batteries of topographical memory tests, in particular real-life tests, to identify such deficits. *Neurology*® 2014;83:1-8

GLOSSARY

CompT = computerized topographical memory tasks; **EcolT** = ecological topographical orientation task; **FDR** = false discovery rate; **PCAI** = posterior cerebral artery infarction; **VLSM** = voxel-based lesion-symptom mapping; **VOI** = volume of interest; **VOSP** = Visual Object and Space Perception battery.

Posterior cerebral artery infarctions (PCAI) account for 5%–25% of ischemic strokes.^{1–3} Visual field defect is the main symptom, followed by memory impairment, aphasia, dyslexia, hallucinations, hemineglect, visual agnosia, and achromatopsia.⁴ Topographical disorientation, defined as impaired orientation in familiar surroundings, is also sometimes reported^{5–9} but has never been systematically studied. Such low interest in topographical memory after PCAI may seem paradoxical given that the topography of infarctions encompasses a wide network of brain areas involved in topographical orientation. Indeed, PCAI generally include the occipital, inferomedial temporal, and posterior parietal lobes,^{4,10} which overlaps with the brain regions (i.e., medial occipital, inferotemporal, posterior parahippocampal, posterior parietal, and retrosplenial cortices) identified by neuropsychological and functional neuroimaging studies investigating topographical memory.^{9,11–15} Considering the high frequency of PCAI, the lesion topography, and the complaint of the patients, we conducted a systematic investigation of topographical memory in patients with left and right PCAI. Our goal was to study the frequency of topographical memory impairment following PCAI and the relationship between those defects and the localization of lesions.

Supplemental data at Neurology.org

From the Institute of Psychology (T.B.), Université Catholique de Louvain, Louvain-la-Neuve, Belgium; Université de Toulouse UPS & Centre de Recherche Cerveau et Cognition (CNRS) (T.B., E.J.B., C.B.), Cerco, UMR 5549, Toulouse, France; Service de Neurologie et Pôle Neurosciences (B.P., C.B., E.M., N.R., J.-F.A., F.C., J.P.), CHU de Toulouse, France; Imagerie cérébrale et handicaps neurologiques (N.R., J.-F.A., F.C., J.P.), Université de Toulouse UPS, UMR 825, CHU de Toulouse, France; and Imagerie cérébrale et handicaps neurologiques (N.R., J.-F.A., F.C., J.P.), Inserm, UMR 825, CHU de Toulouse, Toulouse, France.

Go to Neurology.org for full disclosures. Funding information and disclosures deemed relevant by the authors, if any, are provided at the end of the article.

METHODS Participants. From June 2010 to September 2013, consecutive patients with PCAI ($n = 21$) from the neurology department of the university hospital of Toulouse Purpan were recruited. Six patients were excluded: 1 had a second stroke, 1 died during the assessment period, 1 was left-handed, and 3 stopped their participation during the protocol. In total, 15 patients with PCAI participated in the entire study (7 with left PCAI [L-PCAI] and 8 with right PCAI [R-PCAI]) (see table e-1 on the *Neurology*[®] Web site at Neurology.org for details regarding the nature of the underlying vascular injury). Patients (12 males, all right-handed) were on average 51.6 years old and their mean educational level was 12.3 years (see details in table 1). All of them completed a volumetric head MRI scan and underwent a comprehensive neuropsychological assessment with a mean delay of 124 days after the stroke. Fifteen healthy participants (9 males) participated in the study as controls (mean age 52.3 years, mean educational level 12.9 years). None of the controls had a history of neurologic or vascular disease, head injury, or alcohol abuse, or had cognitive complaints.

Standard protocol approvals, registrations, and patient consents. All patients and controls gave their written consent after detailed information. The study was approved by the institutional ethics committee (2-11-04; B110027-20).

Vision. All patients had a detailed ophthalmologic assessment including visual field (automated Humphrey field analyzer).

Topographical orientation complaint. Before the neuropsychological assessment, participants were asked whether they had noticed any change in their topographical orientation since their stroke. If so, they had to describe their complaint.

Neuropsychological assessment. First, all participants underwent a set of 9 background standardized tests evaluating memory, language, praxis, and visual functions (see appendix e-1), including the Bells test (to assess hemineglect) and the Visual Object and Space Perception battery (VOSP).¹⁶ Then, they underwent a set of 5 computerized topographical memory tasks (CompT): famous places recognition, new scenes memory, landmark recognition,¹⁷ heading orientation,¹⁷ and route learning¹⁸ (for details see appendix e-1). Afterward, participants were administered an ecological topographical orientation task (EcolT) that took place in the precincts of the hospital ward (figure 1). Participants walked a specified route (length: 850 m, decision points: 30) with the examiner after having been explicitly told to remember the route for a future test. After they reached the end of the route, participants were administered the map drawing task, the picture recognition task, and the picture ordering task. They were then required to walk back to the starting point of the route followed with the examiner (i.e., backward path test) (for details see appendix e-1).

MRI brain scans. MRI scans were performed in all participants using a 3T imager (Achieva; Philips, Best, the Netherlands) located in the Unit INSERM UMR825, Toulouse, France. Patients and controls underwent high-resolution anatomical images using a 3D T1-weighted sequence (in-plane resolution 1×1 mm, slice thickness 1 mm, field of view 240×240 mm, and 170 contiguous slices acquired in the sagittal plane, repetition time/echo time 8.1/3.7 msec, flip angle 8°).

Statistical analyses. The Mann–Whitney U test was used for group comparisons between controls and patients and between L-PCAI and R-PCAI. Spearman rank correlation coefficient was used for correlations. These analyses were conducted with SPSS 18.0 (IBM). Due to the large variability of age among patients, in order to analyze individual profiles of patients with L- and

R-PCAI, each patient was compared to the 4 controls with the closest profile in terms of sex and age, since these 2 variables are correlated with topographical orientation.¹⁹ To compare the results of single patients to these controls, a modified t test for small samples was used.²⁰ Performance was considered abnormal when the p value was <0.05 two-tailed. For the analysis of individual profiles, each test was converted to a modified z score based on the mean, the SD, and the control sample size.²⁰

Analysis of brain imaging. Manual delineation of brain lesion was performed by 2 raters (T.B. and C.B.). The boundary of the lesion was manually delineated and filled on the individual native-space MRI using MRICron software (www.mricron.com).²¹ Then, the native original MRIs and the volumes of interest (VOIs) were nonlinearly transformed into Montreal Neurological Institute space (standard template) using SPM8 (Statistical Parametric Mapping, version 8, Wellcome Trust Centre for Neuroimaging, London, UK). Next, we calculated the percentage of overlap between each normalized VOI and Talairach regions according to the Anatomical Automatic Labeling atlas provided by MRICron.²² Finally, we conducted voxel-based lesion-symptom mapping (VLSM),²³ which allowed us to compare the performance of patients with and without a lesion in each voxel, with voxel-wise statistics corrected for multiple comparisons over the whole brain (Brunner-Munzel nonparametric test; threshold: false discovery rate [FDR] $p < 0.05$) (NPM package and MRICron software, <http://www.mccauslandcenter.sc.edu/CRNL/>).

RESULTS Demographics. Patients and controls were comparable in terms of age ($U = 111$; $p = 0.97$) and educational level ($U = 83.5$; $p = 0.23$). Similarly, there was no difference between patients with left and right PCAI in terms of age ($U = 20$; $p = 0.40$) or educational level ($U = 25.5$; $p = 0.78$).

Vision. Visual field defects were found in 12 patients and were equally represented in left and right strokes: homonymous lateral hemianopia (L-PCAI: 3, R-PCAI: 3), homonymous bilateral hemianopia (L-PCAI: 1), homonymous superior quadrantanopia (L-PCAI: 1, R-PCAI: 1), and homonymous inferior quadrantanopia (L-PCAI: 1, R-PCAI: 2) (see figure e-1 for the average visual field defect in L-PCAI and R-PCAI). The level of visual field defect in L-PCAI and R-PCAI was equivalent ($t_{150} = 1.35$; $p = 0.18$).

Standardized neuropsychological tests. Patients obtained a globally normal neuropsychological profile (detailed in table e-2). No patient had signs of low-level perceptual impairment, hemineglect, or simultagnosia (they all succeeded without difficulty on the Bells test and the spatial subtests of the VOSP). No significant difference between L-PCAI and R-PCAI was found.

Computerized topographical memory tasks. Results of controls and patients in the 5 tasks are summarized in table 1. The only significant difference found was between controls and patients in the new scenes memory task ($U = 57.5$; $p < 0.05$).

Ecological topographical orientation task. Results of controls and patients in the subtests are summarized

Table 1 Clinical and demographic data and results of computerized topographical memory tasks and ecological topographical orientation task for patients and controls

	Controls (n = 15)	Patients (n = 15)	L-PCAI (n = 7)	R-PCAI (n = 8)
Clinical and demographic data				
Sex	6F/9M	3F/12M	1F/6M	2F/6M
Age, y	52.3 (13.1)	51.6 (19.5)	55.6 (17.9)	48.1 (21.4)
Educational level, y	12.9 (2.7)	12.3 (3.1)	11.7 (2.4)	12.9 (3.8)
No. with visual field defect	0	12	6	6
No. with topographical memory complaint	0	4	1	3
Computerized topographical memory tasks				
Famous monuments, %	78.11 (11.97)	74.78 (10.14)	72.14 (11.33)	77.09 (9.08)
Famous monuments, RT, msec	3,645 (2,066)	4,302 (2,535)	5,226 (2,716)	3,493 (2,221)
New scenes, %	83.65 (11.11)	75.25 (8.93) ^a	76.19 (10.00)	74.43 (8.49)
New scenes, RT, msec	2,579 (856)	2,351 (1,110)	2,764 (965)	1,990 (1,160)
Landmarks, %	96.67 (6.17)	90.00 (13.09)	84.29 (16.18)	95.00 (7.56)
Landmarks, RT, msec	4,488 (1,318)	6,208 (2,851)	6,975 (3,536)	5,537 (2,106)
Orientation, %	88.67 (10.60)	85.71 (18.28)	80.00 (18.97)	90.00 (17.73)
Orientation, RT, msec	3,464 (1,465)	4,072 (2,054)	4,456 (2,851)	3,783 (1,343)
Route, %	83.11 (15.91)	74.67 (22.14)	75.24 (16.20)	74.17 (27.47)
Route, RT, s	479 (42)	505 (51)	497 (51)	510 (54)
Global score	85.90 (7.67)	79.77 (10.90)	77.06 (12.84)	82.14 (9.07)
Ecological topographical orientation task				
Recognition, %	83.56 (7.50)	73.78 (9.75) ^a	71.90 (10.86) ^a	75.42 (9.07) ^a
Recognition, RT, s	190 (68)	250 (126)	240 (101)	259 (151)
Ordering, %	80.89 (13.54)	63.11 (12.57) ^a	60.95 (13.57) ^a	65.00 (12.22) ^a
Ordering, RT, s	215 (94)	223 (130)	180 (69)	261 (162)
Backward path, %	96.89 (4.95)	84.00 (14.10) ^a	80.48 (13.11) ^a	87.08 (15.06)
Backward path, RT, s	713 (136)	783 (153)	839 (186)	735 (108)
Forward path, RT, s	689 (47)	724 (87)	735 (95)	714 (84)
Forward/backward ratio, %	1.12 (6.99)	3.35 (7.84)	5.75 (7.80)	1.26 (7.75)
Map, %	71.67 (21.63)	48.89 (29.27) ^a	46.19 (31.47)	51.25 (29.16)
Map, RT, s	218 (119)	292 (162)	245 (151)	333 (169)
Global score	83.28 (8.59)	67.44 (13.64) ^a	64.88 (13.68) ^a	69.69 (14.12) ^a

Abbreviations: RT = reaction time; PCAI = posterior cerebral artery infarction.

The top part of the table represents clinical and demographic data: sex, age, educational level, presence of visual field defect, and presence of topographical memory complaint. The middle part of the table shows the results of patients and controls in the computerized topographical memory tasks. The global score represents the average of the percentage of correct responses in the 5 tasks. The bottom part of the table represents the results of patients and controls in the ecological topographical orientation task. The global score represents the average of the percentage of correct responses in the 4 subtests. The Patients column provides the results of L-PCAI and R-PCAI together. Data are mean (SD).

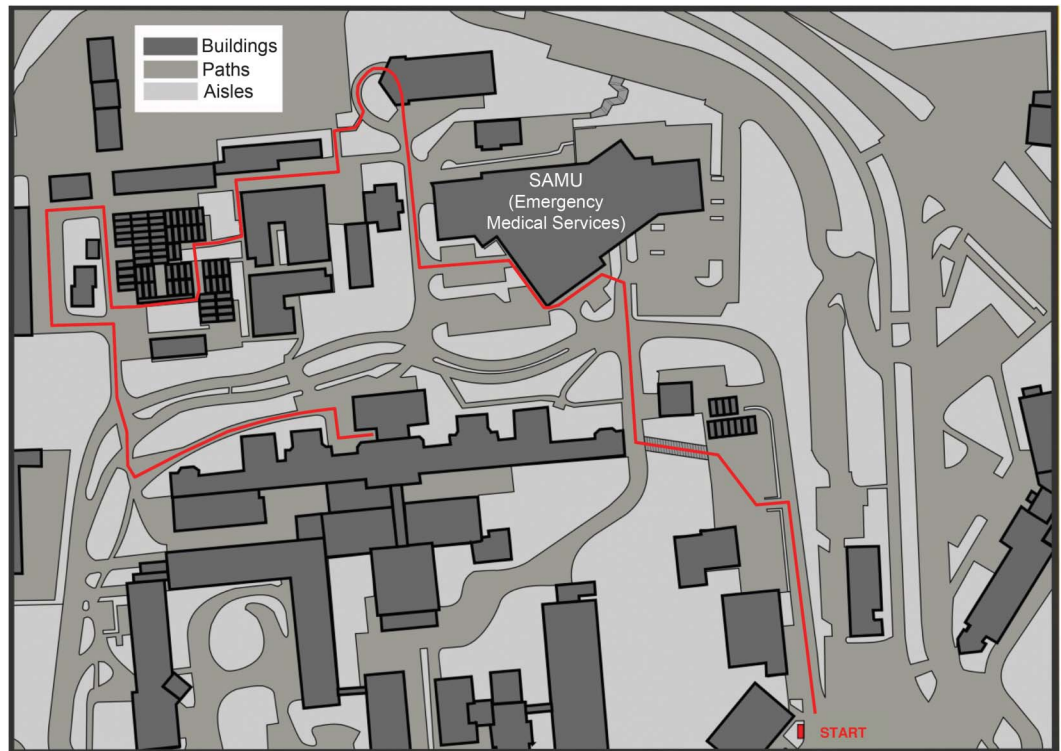
^aSignificant differences between controls vs patients, controls vs L-PCAI, and controls vs R-PCAI (Mann-Whitney *U* test) ($p < 0.05$).

in table 1. Patients with PCAI were significantly impaired in comparison to controls in the 4 subtests: recognition ($U = 47$; $p < 0.01$), ordering ($U = 36.5$; $p < 0.001$), backward path ($U = 43.5$; $p < 0.01$), map ($U = 55$; $p < 0.05$), and global score ($U = 33.5$; $p < 0.001$). Considered separately, patients with L-PCAI had impaired scores in recognition ($U = 20$; $p < 0.05$), ordering ($U = 15$; $p < 0.01$), and backward path ($U = 9.5$; $p < 0.01$) subtests, and were globally impaired ($U = 13.5$; $p < 0.01$). Patients

with R-PCAI had impaired scores in the recognition ($U = 27$; $p < 0.05$) and ordering ($U = 21.5$; $p < 0.05$) subtests and were globally impaired ($U = 22$; $p < 0.05$). No significant difference was found between patients with L-PCAI and R-PCAI.

Computerized vs ecological tasks. Computerized and ecological tasks were highly correlated in the control group ($r = 0.69$; $p < 0.01$) as well as in the patient group ($r = 0.80$; $p < 0.001$) (figure 2). Furthermore,

Figure 1 Drawn-to-scale outline of the hospital representing the route learned in the ecological topographical orientation task



The route consisted of 30 intersections (11 right, 9 straight, and 10 left turns) along 850 m over about 11 minutes. Four tests were administered. Map: participants were asked to draw the entire route on a blank map. Recognition: participants had to decide whether photographs of scenes had been seen or not during the route learning phase (15 targets, 15 distractors). Ordering: participants had to decide which scene had been seen first among 15 pairs of 2 pictures. Backward path: after a delay of 30 minutes, participants were asked to walk the path backward until the starting point.

patients performed better on the computerized task than on the ecological task (Wilcoxon $z = 3.41$; $p < 0.001$; Cohen $d = 1.03$) whereas no difference was found in controls.

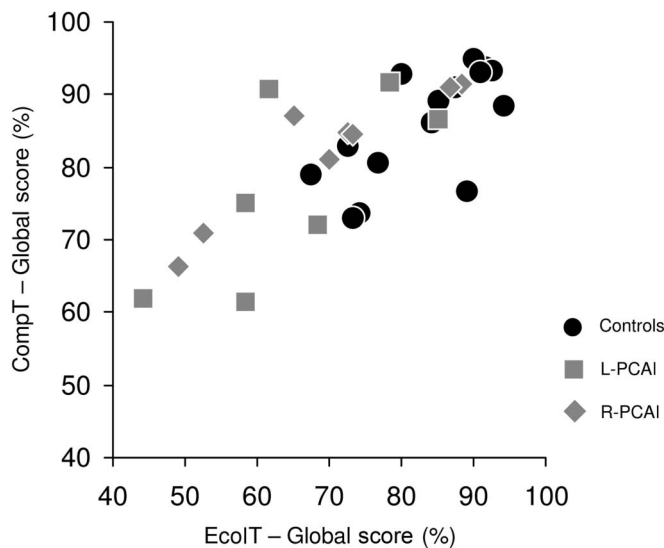
Individual results of the experimental tasks. When comparing each patient to 4 sex- and age-matched controls on computerized tasks, 2 patients with L-PCAI (L1 and L5) and 2 patients with R-PCAI (R2 and R4) were impaired. On the ecological task, 4 patients with L-PCAI (L1, L2, L5, and L7) and 4 patients with R-PCAI (R1, R2, R3, and R4) were impaired (figure 3 and table e-3). Most interestingly, the 4 most impaired patients are the 4 patients who complained about topographical disorientation (L2, R1, R2, and R4). L2 reported that after her stroke she had to reflect more than before about familiar roads she wanted to use. R2 reported having been lost on a very well-known route. R1 complained about difficulties in remembering well-known routes, in recognizing buildings, and in getting oriented in new places. R4 was a taxi driver before his stroke, but he could no longer drive his cab because he got lost in known places and had difficulties planning routes and remembering shortcuts. In the ecological

task, L2 and R4 were impaired in the recognition subtest ($p < 0.05$ and $p < 0.01$, respectively); R1, R2, and R4 were impaired in the ordering subtest (all p values < 0.01); L2, R1, and R4 were impaired in the backward path subtest (all p values < 0.01); and R1, R2, and R4 were impaired in the map subtest ($p < 0.05$, $p < 0.05$, and $p < 0.001$, respectively).

Lesion topography. The average lesion volume was not significantly different statistically between patients with L-PCAI (10.3 mm³) and R-PCAI (6.9 mm³) ($U = 17$; $p = 0.23$) (see table e-4 for details). In patients with R-PCAI, the main lesions were located in the lingual gyrus, calcarine sulcus, and cuneus. In patients with L-PCAI, the main lesions were located in lingual gyrus and calcarine sulcus (see figure 4A and table e-5).

Anatomical-clinical correlations. No correlation was significant between anatomical data and behavioral results in computerized tasks for patients with L- or R-PCAI. Moreover, no correlation was significant between anatomical data and behavioral results in the ecological task in patients with L-PCAI. However, we found significant correlations between anatomical

Figure 2 Correlation between results of computerized and ecological topographical tasks



Correlation between global scores from the computerized topographical memory tasks (CompT) and the ecological topographical orientation task (EcolT) for controls and patients. PCAI = posterior cerebral artery infarction.

data and the ecological task in patients with R-PCAI: the global score of patients with R-PCAI correlated with volume size ($r = -0.88$; $p < 0.01$), percentage of damage to the cuneus ($r = -0.73$; $p < 0.05$), and percentage of damage to the calcarine sulcus ($r = -0.76$; $p < 0.05$). These results were corroborated by VLSM comparing the performance of R-PCAI patients with and without a lesion in each voxel, with voxel-wise z statistics corrected for multiple comparisons over the whole brain (threshold: FDR $p < 0.05$). Significant regions of correlation were located in the right cuneus (923 voxels, 8%) and the right calcarine sulcus (352 voxels, 2.2%) (figure 4B). No significant cluster was found in patients with L-PCAI.

DISCUSSION Our first goal was to determine whether PCAI may result in topographical memory deficits. Our results demonstrate that patients with L-PCAI and R-PCAI indeed present with impairments of spatial memory. Analysis of individual profiles indicated that 8/15 patients presented with impaired spatial memory. Thus, topographical memory deficit is a common consequence of PCAI. However, such impairment was observed more easily on our ecological test of spatial memory than on our computerized tests. This suggests that topographical memory impairments may have been underestimated if only paper-and-pencil or computerized tests are used.

Group analyses demonstrated that patients with L-PCAI and R-PCAI presented with topographical disorientation. However, after a careful look at individual profiles and taking into account the age and

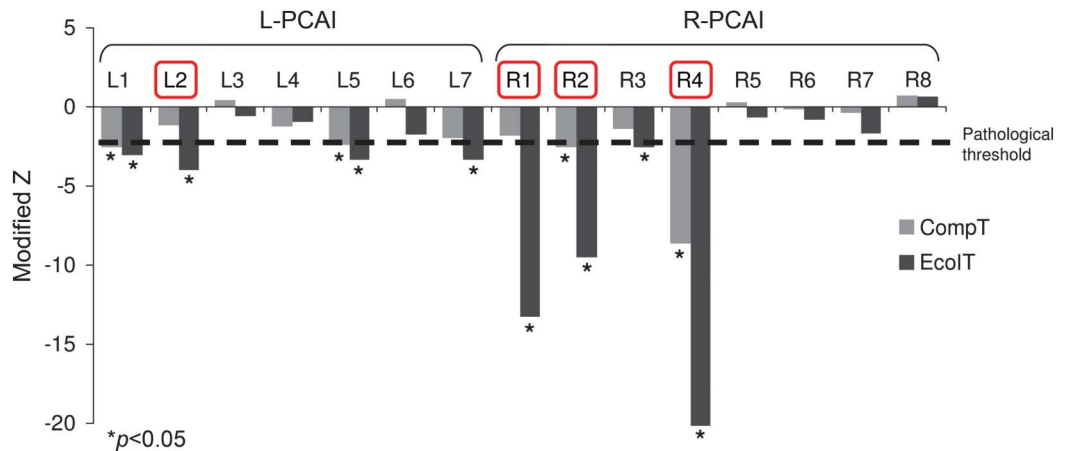
sex of each patient, we demonstrated that patients with R-PCAI were more severely affected than patients with L-PCAI. This difference between patients with left and right PCAI cannot be explained by other variables such as age, sex, educational level, visual field defect, or general neuropsychological profile, since patients with L-PCAI and R-PCAI were equivalent on those variables.

The right hemisphere has long been considered more specialized for the perceptual and cognitive analysis of space.²⁴⁻²⁶ Recently, patients with vascular accident in the territory of the right middle cerebral artery performed worse than patients with left-side damage and controls in a walking spatial span test.²⁷ In another ecological map-following task, patients with right cerebrovascular brain damage performed worse than controls and patients with left brain damage.²⁸ Together with these previous findings, our results demonstrated that while both hemispheres seem involved in spatial memory, the posterior regions of the right hemisphere are particularly crucial in subserving spatial memory mechanisms.

Furthermore, we showed that the most impaired patients were those who complained about topographical orientation difficulties, demonstrating the link between subjective complaint and behavioral results in our tasks. However, only 4 of the 8 patients with impaired performance explicitly complained. Anosognosia of visual perception defects is frequent in patients with PCAI, particularly when lesions encompass the lingual gyrus and the cuneus.²⁹ This would explain why 50% of the patients who were impaired did not consciously recognize their topographical disorientation. Alternatively, the 4 less impaired patients may not have noticed their deficits because they were too subtle to be noticed in real-life routine navigation.

Our results demonstrated that our ecological topographical orientation task was much more sensitive than the computerized tasks. Indeed, while patients and controls globally obtained the same performance in the computerized tasks, patients were significantly impaired in all the subtests of the ecological task. This difference cannot be explained by a difference in difficulty, since CompT and EcolT were performed equally well by controls. These results are in line with previous studies that demonstrated the higher validity of ecological tests in wayfinding assessment.^{30,31} This discrepancy between classical or computerized tasks and ecological assessment could be explained by the fact that route learning in the real world depends on strategies in selecting perspectives and attending to landmarks in the distance that are missing in paper-and-pencil tests or when using standard screens. These results support the use of ecological tasks as predictors of wayfinding skills and of real-world functioning in PCAI.

Figure 3 Individual profiles of the 15 patients with PCAI in CompT and EcolT

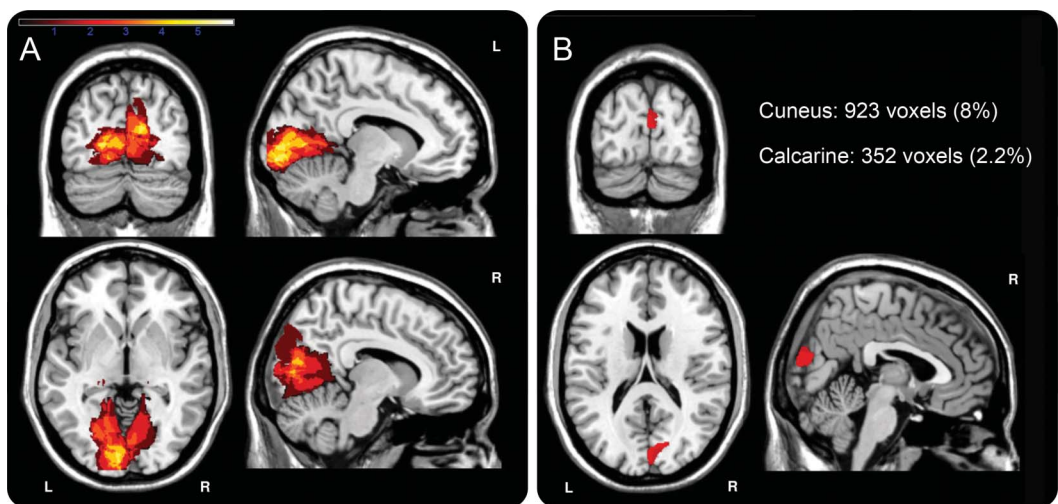


Individual profiles of each of the patients with PCAI compared to the 4 best-matched control participants. Modified z values were provided by the modified t test of Crawford and Howell (1998) for single-case studies. In total, 4 patients were impaired in the CompT tasks (L1, L5, R2, and R4) and 8 patients were impaired in the EcolT task (L1, L2, L5, L7, R1, R2, R3, and R4). All the patients impaired in CompT were also impaired in EcolT. Red rectangles indicate the 4 patients who complained about topographical disorientation. CompT = computerized topographical memory tasks; EcolT = ecological topographical orientation task; PCAI = posterior cerebral artery infarction.

The anatomical regions correlating with the behavioral performance were located in the cuneus and calcarine sulcus of the right hemisphere. This appears to be in line with a set of studies that demonstrated that the activity of the cuneus specifically increases in tasks of wayfinding³² and familiar places recognition³³ and in retrieval of objects location.³⁴ A recent study also found that the gray matter volume of the cuneus correlated with performance in a virtual

water maze task.³⁵ Another set of studies found that the right calcarine sulcus is involved in learning in navigational space.^{36–38} The calcarine sulcus is also sometimes considered part of what was called the “retrosplenial complex,”³³ which is defined as a functional region including the anatomically defined retrosplenial cortex (Brodmann areas 29 and 30), the posterior cingulate (area 23), and the anterior calcarine region. We indeed found lesions in the

Figure 4 Overlap of lesion territories in patients with L-PCAI and R-PCAI and VLSM results



(A) Overlap of lesion territories in patients with left and right posterior cerebral artery infarction (PCAI). The color scale from red to yellow represents the increasing number of patients with damage. Dark red represents regions where only 1 patient had damage. Light yellow represents regions where 5 patients had damage. In R-PCAI, the lesions were mainly located in lingual gyrus, calcarine sulcus, and cuneus. In L-PCAI, the main lesions were located in lingual gyrus and calcarine sulcus. (B) Voxel-based lesion-symptom mapping (VLSM) comparing the performance of R-PCAI patients with and without a lesion in each voxel, with voxel-wise z statistics corrected for multiple comparisons over the whole brain (threshold: false discovery rate $p < 0.05$). Significant regions are located in the cuneus (923 voxels, 8%) and the calcarine sulcus (352 voxels, 2.2%).

retrosplenial cortex as well as in the retrosplenial complex in our patients with topographical disorientation (see table e-5). However, the VLSM results demonstrated that the region correlating significantly with the deficits was more posterior, in Brodmann area 18 at the level of the cuneus and the calcarine sulcus.

Finally, it was suggested that visuospatial processing is subtended by the occipital-parietal circuit (also called dorsal stream) and 3 parietal pathways emerging from the dorsal stream: a parieto-prefrontal pathway (supporting spatial working memory), a parieto-premotor pathway (supporting visually guided actions), and a parieto-medial temporal pathway, which links the parietal lobe to the parahippocampal gyrus and the medial temporal lobe (supporting landmark processing and spatial navigation).³⁹ The latter pathway is connected to the occipital-parietal network via the angular gyrus. The angular gyrus shows strong functional connectivity with the precuneus and area V6, which are strongly connected with early visual areas in the region of the calcarine sulcus and the cuneus (see figure 3 in reference 39). Our patients who performed poorly in the ecological topographical orientation task might have a lesion that interrupts the occipito-parietal pathway and disconnects the parieto-medial temporal pathway. This could explain the specific navigational impairments in our R-PCAI patients with lesions of the cuneus or the calcarine sulcus that are located on the occipito-parietal pathway. As a result, these patients would present with impairment in landmark recognition and navigation because of a disconnection of the parieto-medial temporal pathway.

Anterograde topographical disorientation was previously associated with medial inferior occipital and medial occipitotemporal lesions, especially in the posterior parahippocampal gyrus.^{8,9,13} In a recent study on patients with cerebrovascular brain damage, significant associations were evidenced between lesioned voxels and spatial errors in the right putamen, superior longitudinal fasciculus, and superior corona radiata.²⁹ In another study on patients with PCAI, an overlap of lesions was found in the fusiform and parahippocampal gyrus in patients with impairment in house pictures memory.⁴⁰ Considering our results together with these previous findings, spatial cognition relies on a posterior network of brain areas, mostly right lateralized, that are likely often damaged in PCAI.

We conducted a systematic investigation of topographical memory in patients with left and right PCAI. Patients were recruited after a first and unique stroke, they were all at a chronic stage (average 4 months postinfarct), and they underwent an extensive battery of behavioral, computerized, and ecological tests. This study allowed us to demonstrate that topographical memory impairment is a frequent trait

following PCAI, provided that sufficiently sensitive tests are used and considering the fact that patients often fail to consciously recognize their topographical disorientation. These results should encourage the systematic assessment of topographical memory with dedicated tests after PCAI.

AUTHOR CONTRIBUTIONS

Dr. T. Busigny: study concept and design, analysis and interpretation. B. Pagès: study concept and design, acquisition of data. Dr. E.J. Barbeau: study concept and design, critical revision of the manuscript for important intellectual content. C. Bled: acquisition of data. E. Montaut: acquisition of data. Dr. N. Raposo: critical revision of the manuscript for important intellectual content. Dr. J.-F. Albucher: critical revision of the manuscript for important intellectual content. Pr. F. Chollet: critical revision of the manuscript for important intellectual content. Pr. J. Pariente: study supervision.

ACKNOWLEDGMENT

The authors thank Aiden Arnold, Ford Burles, and Giuseppe Iaria for sharing their tasks of landmark recognition and heading orientation, and Laure Saint-Aubert and Federico Nemmi for their priceless help in brain imaging analysis. They also thank Marion Sarraill and Aude Deramond for testing patients, Ephraïm Partouche for his help with brain lesions delineation, Gwenael Bourcier for the drawing in figure 1, and Nadine Betbeder for her investment in creating the computerized spatial memory tasks. They thank Federico Nemmi and Giuseppe Iaria for their comments on a previous version of the manuscript and 2 anonymous reviewers for their helpful remarks. Finally, the authors thank Nathalie Vayssière, Hélène Gros, Lucette Foltier, and Jean-Pierre Désirat of the IRM technical platform (INSERM UMR825) for their priceless assistance.

STUDY FUNDING

Thomas Busigny was supported by the Belgian National Fund for Scientific Research (FRS-FNRS).

DISCLOSURE

T. Busigny, B. Pagès, E. Barbeau, C. Bled, E. Montaut, and N. Raposo report no disclosures relevant to the manuscript. J.-F. Albucher received honoraria for medical scientific meetings from Bayer and Boehringer Ingelheim. F. Chollet is a consultant for Institut de recherche Pierre Fabre, Pfizer, and Boston Scientific. J. Pariente serves as an editorial board member of *Journal of Alzheimer's Disease* and has received research grants from Avid Radiopharmaceuticals. Go to Neurology.org for full disclosures.

Received April 14, 2014. Accepted in final form June 19, 2014.

REFERENCES

1. Yamamoto Y, Georgiadis AL, Chang HM, Caplan LR. Posterior cerebral artery territory infarcts in the New England Medical Center Posterior Circulation Registry. *Arch Neurol* 1999;56:824–832.
2. Brandt T, Steinke W, Thie A, Pessin MS, Caplan LR. Posterior cerebral artery territory infarcts: clinical features, infarct topography, causes and outcome. Multicenter results and a review of the literature. *Cerebrovasc Dis* 2000;10:170–182.
3. Arboix A, Arbe G, Garcia-Eroles L, Oliveres M, Parra O, Massons J. Infarctions in the vascular territory of the posterior cerebral artery: clinical features in 232 patients. *BMC Res Notes* 2011;4:329.
4. Cals N, Devuyst G, Asfar N, Karapanayiotides T, Bogousslavsky J. Pure superficial posterior cerebral artery territory infarction in the Lausanne Stroke Registry. *J Neurol* 2002;249:855–861.

5. Kraft A, Grimsen C, Kehrer S, et al. Neurological and neuropsychological characteristics of occipital, occipito-temporal and occipito-parietal infarction. *Cortex* 2014; 56:38–50.
6. Habib M, Sirigu A. Pure topographical disorientation: a definition and an anatomical basis. *Cortex* 1987;23:73–85.
7. Milandre L, Brosset C, Botti G, Khalil R. A study of 82 cerebral infarctions in the area of posterior cerebral arteries. *Rev Neurol (Paris)* 1994;150:133–141.
8. Barrash J. A historical review of topographical disorientation and its neuroanatomical correlates. *J Clin Exp Neuropsychol* 1998;20:807–827.
9. Aguirre GK, D'Esposito M. Topographic disorientation: a synthesis and taxonomy. *Brain* 1999;122:1613–1628.
10. Park KC, Yoon SS, Rhee HY. Executive dysfunction associated with stroke in the posterior cerebral artery territory. *J Clin Neurosci* 2011;18:203–208.
11. Epstein R, Kanwisher N. A cortical representation of the local visual environment. *Nature* 1998;392:598–601.
12. Aguirre GK, Zarahn E, D'Esposito M. Neural components of topographical representation. *Proc Natl Acad Sci U S A* 1998;95:839–846.
13. Barrash J, Damasio H, Adolphs R, Tranel D. The neuroanatomical correlates of route learning impairment. *Neuropsychologia* 2000;38:820–836.
14. Epstein RA. Parahippocampal and retrosplenial contributions to human spatial navigation. *Trends Cogn Sci* 2008; 12:388–396.
15. Vann SD, Aggleton JP, Maguire EA. What does the retrosplenial cortex do? *Nat Rev Neurosci* 2009;10:792–802.
16. Warrington EK, James M. *The Visual Object and Space Perception Battery*. Bury St Edmunds: Thames Valley Test Company; 1985.
17. Arnold AE, Burles F, Krivoruchko T, et al. Cognitive mapping in humans and its relationship to other orientation skills. *Exp Brain Res* 2013;224:359–372.
18. Barbeau EJ, Didic M, Felician O, et al. Pure progressive amnesia: an atypical amnesic syndrome? *Cogn Neuropsychol* 2006;23:1230–1247.
19. Liu I, Levy RM, Barton JJS, Iaria G. Age and gender differences in various topographical orientation strategies. *Brain Res* 2011;1410:112–119.
20. Crawford JR, Howell DC. Comparing an individual's test score against norms derived from small samples. *Clin Neuropsychologist* 1998;12:482–486.
21. Rorden C, Karnath HO, Bonilha L. Improving lesion-symptom mapping. *J Cogn Neurosci* 2007;19:1081–1088.
22. Tzourio-Mazoyer N, Landeau B, Papathanassiou D, et al. Automated anatomical labeling of activations in SPM using a macroscopic anatomical parcellation of the MNI MRI single-subject brain. *Neuroimage* 2002;15:273–289.
23. Bates E, Wilson SM, Saygin AP, et al. Voxel-based lesion-symptom mapping. *Nat Neurosci* 2003;6:448–450.
24. Newcombe F, Russel WR. Dissociated visual perceptual and spatial deficits in focal lesions of the right hemisphere. *J Neurol Neurosurg Psychiatry* 1969;32:73–81.
25. Ratcliff G, Newcombe F. Spatial orientation in man: effects of left, right, and bilateral posterior cerebral lesions. *J Neurol Neurosurg Psychiatry* 1973;36:448–454.
26. De Renzi E, Faglioni P, Previdi P. Spatial memory and hemispheric locus of lesion. *Cortex* 1977;13:424–433.
27. Piccardi L, Iaria G, Bianchini F, Zompanti L, Guariglia C. Dissociated deficits of visuo-spatial memory in near space and navigational space: evidence from brain-damaged patients and healthy older participants. *Neuropsychol Dev Cogn B Aging Neuropsychol Cogn* 2011;18:362–384.
28. Palermo L, Ranieri G, Boccia M, Piccardi L, Nemmi F, Guariglia C. Map-following skills in left and right brain-damaged patients with and without hemineglect. *J Clin Exp Neuropsychol* 2012;34:1065–1079.
29. Baier B, Geber C, Müller-Forell W, Müller N, Dieterich M, Karnath HO. Anosognosia for obvious visual field defect in stroke patients. *Brain Struct Funct Epub* 2014 March 21.
30. Naldone MJ, Stringer AY. Ecologic validity in neuropsychological assessment: prediction of wayfinding. *J Int Neuropsychol Soc* 2001;7:675–682.
31. Monacelli AM, Cushman LA, Kavcic V, Duffy CJ. Spatial disorientation in Alzheimer's disease: the remembrance of things passed. *Neurology* 2003;61:1491–1497.
32. Hartley T, Maguire E, Spiers HJ, Burgess N. The well-worn route and the path less traveled: distinct neural bases of route following and wayfinding in humans. *Neuron* 2003;37:877–888.
33. Epstein RA, Parker WE, Feiler AM. Where am I now? Distinct roles for parahippocampal and retrosplenial cortices in place recognition. *J Neurosci* 2007;27:6141–6149.
34. de Rover M, Petersson KM, van der Werf SP, Cools AR, Berger HJ, Fernandez G. Neural correlates of strategic memory retrieval: differentiating between spatial-associative and temporal-associative strategies. *Hum Brain Mapp* 2008;29:1068–1079.
35. Mueller SC, Merke DP, Leschek EW, et al. Grey matter volume correlates with virtual water maze task performance in boys with androgen excess. *Neuroscience* 2011;197:225–232.
36. Iaria G, Chen JK, Guariglia C, Pito A, Petrides M. Retrosplenial and hippocampal brain regions in human navigation: complementary functional contributions to the formation and use of cognitive maps. *Eur J Neurosci* 2007;25:890–899.
37. Nemmi F, Boccia M, Piccardi L, Galati G, Guariglia C. Segregation of neural circuits involved in spatial learning in reaching and navigational space. *Neuropsychologia* 2013; 51:1561–1570.
38. Nemmi F, Piras F, Péran P, Incoccia C, Sabatini U, Guariglia C. Landmark sequencing and route knowledge: an fMRI study. *Cortex* 2013;49:507–519.
39. Kravitz DJ, Saleem KS, Baker CI, Mishkin M. A new neural framework for visuospatial processing. *Nat Rev Neurosci* 2011;12:217–230.
40. Martinaud O, Pouliquen D, Gérardin E, et al. Visual agnosia and posterior cerebral artery infarcts: an anatomical-clinical study. *PLoS One* 2012;7:e30433.